

9-1963

The Leucoplakic Vulva: Premalignant Determinants

C. Paul Hodgkinson

Roy B. P. Patton

M. A. Ayers

Follow this and additional works at: <https://scholarlycommons.henryford.com/hfhmedjournal>

 Part of the [Life Sciences Commons](#), [Medical Specialties Commons](#), and the [Public Health Commons](#)

Recommended Citation

Hodgkinson, C. Paul; Patton, Roy B. P.; and Ayers, M. A. (1963) "The Leucoplakic Vulva: Premalignant Determinants," *Henry Ford Hospital Medical Bulletin* : Vol. 11 : No. 3 , 279-287.

Available at: <https://scholarlycommons.henryford.com/hfhmedjournal/vol11/iss3/3>

This Article is brought to you for free and open access by Henry Ford Health System Scholarly Commons. It has been accepted for inclusion in Henry Ford Hospital Medical Journal by an authorized editor of Henry Ford Health System Scholarly Commons. For more information, please contact acabrer4@hfhs.org.

THE LEUCOPLAKIC VULVA

Premalignant Determinants

C. PAUL HODGKINSON, M.D.,* ROY B. P. PATTON, M.D.,**

AND M. A. AYERS, M.D.*

IN A PAPER proposing to discuss the leucoplakic vulva and any predisposing tendency it may have to the development of squamous cell carcinoma, the term "pre-malignant" has presumptuous connotations. This is presumptuous because it implies that more is known about cancer and its mode of development than can be supported by facts. What happens in the cell prior to the stage of carcinoma-in-situ is a burning and unsolved question in cancer research. How to detect and appraise the parameters of malignant potential is the essence of meaning connoted by the word "pre-malignant".

With these limitations fully in mind, it is proposed in this discussion to reappraise the "white spot" diseases of the vulva for premalignant determinants. The basis for the report comes from a conjoined effort by the departments of gynecology-obstetrics and pathology to reevaluate the clinical findings and the cellular pathology of these hyperkeratinizing diseases. The project was undertaken with hopes to clarify the terms of the dermatologist, the definitions of the pathologist, and the confusion and bewilderment of the gynecologist, respectively.

In scope the subject matter is limited to the dystrophic changes in vulvar skin which are known, or have been suspected, to predispose to squamous cell carcinoma. Omitted from consideration are the rarer forms of malignancy, i.e., sarcoma, melanocarcinoma, Paget's disease, basal cell carcinoma, and adenocarcinoma of Bartholin gland. Also eliminated from direct discussion are Bowen's disease and intraepithelial carcinoma (carcinoma-in-situ) because these conditions represent established malignancy, not premalignancy.

Definition of Terms

Premalignancy may be defined as the internal, external, and temporal environment which precedes and predisposes the development of malignant changes in cells.

* Department of Gynecology and Obstetrics

**Department of Pathology

The premalignant lesion must have a identifiable degree of similarity to its malignant counterpart. By definition, the lesion must be reversible in its tendency to become malignant and, if completely removed, it must not recur as malignancy. If left undisturbed a premalignant lesion will eventually become malignant, according to a predictable rate of incidence which is peculiar to conditions inherent to that organ.

At this time scientific advancement has not reached the point that these qualifications can be met for cancer of any type. Coming closest are some of the borderline stages of carcinoma-in-situ. However, not enough is known about cellular behavior to obtain consistent results. Perhaps improved supravital staining methods, more comprehensive tissue enzyme studies, and superior microscopic morphologic technics will be available eventually to solve this problem.

This limitation in basic knowledge places a primary and major handicap upon the scientific worth of this study. With no recourse to precisely defined parameters of malignant potential, results must be equated indirectly through the use of crude and inaccurate end-points, such as rates of cancer occurrence.

Morphopathology

Skin is a compound organ that has a dual embryology: The epidermis arises from the ectoderm; the dermis from the mesoderm. Dividing the two components is the basement membrane upon which lies the basal layer of the epidermis. Next outwardly comes the multirowed prickle cells, then the thin granular layer, and finally the horny or keratin layer. Deep to the basement membrane is the dermis which is composed of 90 per cent collagen fibers which are interwoven with elastic fibers. The dermis also contains blood vessels, lymphatics, tactile sensory organs, and the basement-membrane covered epidermal appendages: hair follicles, sebaceous glands, apocrine glands, and eccrine glands.

In serving its sexual reproductive functions, the skin of the vulva is subjected to uncommon degrees of physical and chemical trauma. The growth and character of the skin of the vulva is under the influence of the adrenal and ovarian hormones; consequently, it goes through major changes during puberty and menopause.

In this discussion the foci of interest are (1) the horny or keratin layer and (2) the prickle cell layer. The pathology of leucoplakia, the "white spot" is hypertrophy of the horny layer or hyperkeratinization; it may be a physiopathologic expression of stimulated growth of the underlying cell layers or it may indicate over-retention and accumulation of keratin with atrophy of the underlying cells.

Leucoplakia, kraurosis, and lichen sclerosus vel atrophicus constitute a triad of "white spot" diseases of the vulva. As signals of premalignancy, they will be considered first for their historical interest; then an effort will be made to place them in current knowledge of histopathology.

THE LEUCOPLAKIC VULVA

HISTORICAL

Leucoplakia: according to Parrott and Miller¹ the word "leucoplakia" was coined by Schwimmer (1877) to describe a white plaque on the buccal mucosa. Morris (1882) applied the term white spots on the vulva. As first described, the word was intended for macroscopic description and was derived from "leucos" meaning white and "placos" meaning flat plaque.

Confusion over the term "leucoplakia" arose when it was appreciated that the lesion was often associated with malignancy. Research was stimulated and a number of investigators tried to classify the lesion histologically. In 1908 Bonney² clarified the histopathology and stated that "leucoplakia" and leucoplakic "vulvitis" were different stages of the same disease. Bonney^{2,3} identified leucoplakia vulvitis as a three-stage disease: 1. early or hypertrophic, 2. intermediate or mixed, and 3. late or atrophic. Berkeley and Bonney⁴ (1909) recognized that leucoplakia was a progressive disease and they differentiated between "kraurosis" and "leucoplakic vulvitis,," Langley, Hertig, and Van Smith⁵ (1951) attempted to define the histopathology similar to the stages of Bonney. In the early stage, the epithelium showed keratinization and hypertrophy and thickened rete pegs which reached deeply into the corium. The late stage showed atrophy of the epithelium, excess keratinization, and absent or short pegs. The intermediate stage showed characteristics of both the early and late stages. The changes in the corium in all epithelial stages were characterized by atrophy, decrease in elastic fibers and replacement by collagen fibers, decrease in hair follicles and glands, round cell infiltration, and decrease in the number of blood vessels.

It was soon evident that efforts to qualify histopathology of leucoplakia only compounded the enigma. Hyperkeratosis was the only common finding in all stages. This has put the problem back to the clinician because the common pathologic feature of the "white spot" was hyperkeratosis. As the result, the clinician has claimed it to be a pathologic entity; the pathologist has claimed it to be a clinical lesion.

Kraurosis: the second "white spot" disease of the vulva has been equally controversial. Jeffcoate and Woodcock⁶ stated that disagreement about kraurosis extended even to the name. Breisky (1885) according to Parrott and Miller used the term to indicate a peculiar shrinking of the vulva which differed from simple senile atrophy. Hunt⁷ considered kraurosis to be a clinical syndrome, not a pathologic entity, and Lever stated that, practically, it was identical to lichen sclerosus vel atrophicus. Most have agreed that kraurosis has no distinct histopathology. Berkeley and Bonney (1909) claimed that kraurosis never predisposed to malignancy and thus differed from leucoplakia. Taussig⁸ differentiated between kraurosis and atrophic leucoplakia and agreed that the former did not predispose to malignancy. Today a strong feeling has developed that the term "kraurosis" had best be discarded because it has neither clinical nor pathologic preciseness.

Lichen sclerosus vel atrophicus: the third "white spot" disease, is a dermatological syndrome. It appears over other parts of the body, involves women of all

ages, and tends to resolve spontaneously. Distinguishing features are the tendency for lichen sclerosus vel atrophicus to spread to the introitus where it causes stenosis and narrowing and the tendency for it to spread to the perianal areas. Microscopically, the lesion cannot be accurately differentiated from kraurosis.

Current Status of "White Spot" Diseases

In the United States, led by the strong convictions of Taussig⁸, and in England by similar attitudes of Berkeley and Bonney⁴, that leucoplakia was premalignant, if not actually malignant, a few years ago vulvectomy became the order of the day for all patients with "white spot" disease of the vulva. Gradually this procedure has been given up because the high rate of recurrence of the disease was soon noted and because the predicted malignancy failed to occur. Today there is a trend to treat white keratinized lesions as "possibly" premalignant and biopsy is gradually replacing vulvectomy.

However, for the most part, the modern clinician remains as confused as ever about the concepts of the "white spot" disease. He is bewildered by the glib terms confidently used to describe vulvar lesions. Also hard-put-to, is the pathologist when he tries arbitrarily to fit the histopathology to a distinct pathologic or clinical entity.

Jeffcoate and Woodcock⁵, and MacAfee⁹, critically appraised the chronic vulval lesions in efforts to resolve the dilemma of the "white spot" diseases. They concluded that the three diseases should be equated under a common designation because they all show the same basic pathology. Jeffcoate and Woodcock proposed the all-embracing and noncommittal clinical title: "chronic epithelial dystrophy". MacAfee has endorsed this suggestion. Jeffcoate and Woodcock emphasized that the "pathologist equally should be untrammelled by the need to append precise dermatological nomenclature to his report — his factual description — should include an assessment of the activity and orderliness of the squamous epithelium."

The feeling is rather general that leucoplakia is a relatively specific reaction to nonspecific stimuli. Also, opinions are rather strong that the tendency for leucoplakia to predispose to malignancy is an expression that is a part of a local and general field change; and, in that individual and in that local area, there is a tendency for malignancy to develop in multiple foci. McKelvey¹⁰ stated that the incidence of vulvar cancer paralleled the age-specific index curve in Minnesota and that there was the statistic probability that all females would develop cancer of the vulva if they survived sufficiently long.

Current Project

The project which forms the basis for this report was undertaken to determine if the older and possibly obsolete attitudes toward chronic lesions of the vulva could be revised. In an effort to up-date clinical handling, multiple biopsy was substituted for simple vulvectomy. Each biopsy site was identified with numbers on a "vulval map". The numbered specimens were placed in separate containers for identification

THE LEUCOPLAKIC VULVA

by the pathologist (R.B.P.). Skin samples were obtained from areas showing atrophy as well as hypertrophy because malignancy may occur in either.

Pathologic interpretation has been made according to the principles of cellular pathology. Opinions as to what constitutes premalignant tendencies have been based upon prescribed and definite cellular features and not upon histomorphologic patterns previously identified with leucoplakia.

Pseudo-epitheliomatous hyperplasia is an apt descriptive term used by pathologists to indicate a lesion that microscopically looks malignant at low power magnification. Masses of hyperplastic prickle cells thicken the epidermis and extend deeply into the dermis. However, high power examination of these cells shows that they lack the typical nuclear and cytoplasmic features of a premalignant or malignant lesion (Figure 1).

This type of reaction occurs in conjunction with ulcerative and scarring lesions, and it frequently overlies granular cell myoblastoma and melanoma. Pseudo-epitheliomatous hyperplasia as well as epidermoid carcinoma can be produced experimentally by the application of tars and lubricating oils. The two conditions occur clinically in "mule spinner's" and "chimney sweep's" cancer. According to Jeffcoate and Woodcock⁵ lubricating oil was incriminated in the development of vulvar cancer when Gerrard (1932) showed that women operatives in the cotton and woolen mills in England who were exposed to oil-impregnated waste material of their trade, developed carcinoma of the vulva at twice the rate of women of corresponding ages who were employed in other trades.

Thus, pseudo-epitheliomatous hyperplasia fulfils some of the requirements of a premalignant lesion but, as defined pathologically, it is neither malignant nor premalignant.

"Premalignant" as adopted for this study was defined by the following characteristics: hyperkeratosis, acanthosis (prickle cell hyperplasia), irregular rete ridges and epithelial cell atypism, and dyskeratosis involving the lower portion of the epithelium (Figure 2). Epithelial cell atypism has been considered most important it is characterized by cellular and nuclear variation in size and in staining reactions, by the tendency to loss of polarity, and by irregular keratinization.

On the other hand, carcinoma-in-situ consists of these same features but the epithelial atypism and dyskeratosis involves the full thickness of the epithelium. There is undifferentiation or lack of normal maturation of the entire thickness of the epithelial layers (Figure 3).

Instances of border-line microscopic findings have been observed. Occasionally encountered in the lower half of the epithelial thickness were changes suggestive of in-situ malignancy. The critical decision for the pathologist has been to differentiate

between "actual" and "tendency toward" malignancy. The diagnosis then became a matter of judgment. Only time, constant clinical observation, and repeated biopsy can finely settle the problem for those patients whose lesions have been diagnosed as premalignant. Those patients diagnosed as having in-situ carcinoma were subjected to wide simple vulvectomy.

Currently we have adopted a double standard of pathology reporting for "white spot" lesions of the vulva. In addition to the historic leucoplakia-kraurosis-lichen sclerosus vel atrophicus classification, an effort has been made to qualify specimens according to premalignant features. Specimens are qualified according to the following "project diagnosis":

1. "negative for premalignant features."
2. "postive for premalignant features."
3. "carcinoma, intraepithelial."
4. "carcinoma, invasive."

In a recent group of 22 consecutive patients a total of 76 biopsy specimens was obtained. One patient had 10 separate sites biopsied. A total of 37 diagnoses was obtained with up to 3 distinct lesions identified in the same patient. The lesions varied from leucoplakia to condylomata, and each specimen was additionally classified according to project standards. The average number of biopsies per patient was 3.5, and the average number of diagnoses per patient was 1.7.

Because this project has been in progress for only about 2 years, only a preliminary report of the results can be made at this time. Selected reports of interesting cases illustrate the more important observations which have been made. The importance of obtaining multiple biopsy specimens is evident in the following case reports.

CASE REPORTS

CASE 1 — Hyperkeratosis and prickle cell hyperplasia. (I.W.) Age 63, multipara, symptoms of vulvar irritation of 2 weeks duration.

Clinical examination: Entire vulva involved with scaly, leucoplakic changes, and with 2 areas of ulceration.

Treatment: 10 biopsy specimens.

Pathologic final diagnosis: 1. Lichen sclerosus vel atrophicus (3 specimens). 2. Leucoplakia with hyperplasia and chronic inflammation (4 specimens). 3. Kraurosis, epithelial atrophy and chronic inflammation (3 specimens).

Project diagnosis: Positive for premalignant features (4/10 specimens).

CASE 2 — Hyperkeratosis and prickle cell atrophy — Leucokeratosis: (B.R.) Age 57, para 2, complained of itching, burning and pain of vulva for 10 years duration.

Clinical examination: Leucoplakia, excoriation, thickened skin involving vulva and perianal areas.

THE LEUCOPLAKIC VULVA

Treatment: 7 biopsy specimens.

Pathologic final diagnosis 1. Leucoplakia (4 specimens). 2. Leukokeratosis (1 specimen). 3. Psoriaform dermatitis (2 specimens).

Project diagnosis: Positive for premalignant features (4/7 specimens).

CASE 3 — Pseudo-epitheliomatous hyperplasia. (J.V.) Age 72, para 2, with past history of carcinoma of breast 9 years previously, complained of irritation of vulva for many years and a slight bloody vaginal discharge of one week duration.

Clinical examination: Erythematous, scaly, thin, shiny skin of vulva with areas of leucoplakia. Cervix hard but not ulcerated.

Treatment: 8 biopsy specimens of vulva and biopsy of cervix.

Pathologic final diagnosis: 1. Cervix, squamous cell carcinoma staged clinically as international I A. 2. Vulva, pseudo-epitheliomatous hyperplasia.

Project diagnosis: Possibly positive for premalignant features (0/8 specimens).

CASE 4 — Carcinoma-in-Situ vulva. (M.M.) Age 62, para 2.

Clinical examination: Ulcerated, whitened left labia.

Treatment: Biopsy of vulva — 6 specimens.

Pathologic final diagnosis: Intraepithelial carcinoma, vulva.

Project diagnosis: Carcinoma, intraepithelial (6/6 specimens).

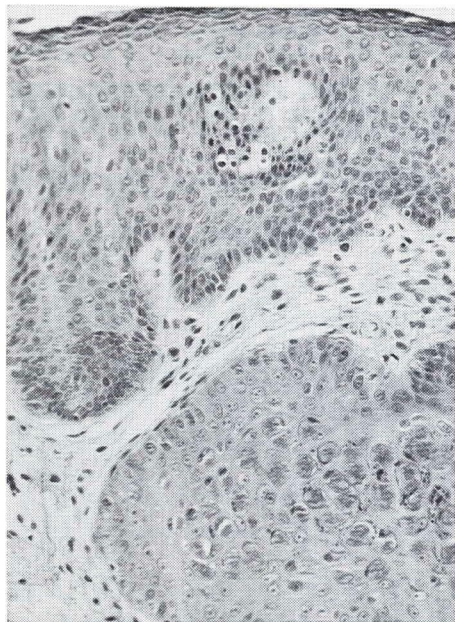


Figure 1

Pseudoepitheliomatous hyperplasia, biopsy of vulva. Epithelium is hyperplastic and maturation is proceeding normally. The large mass of hyperplastic squamous cells in lower half was in continuity with surface epithelium. (All figures at 325x and from hematoxylin and eosin stained sections.)

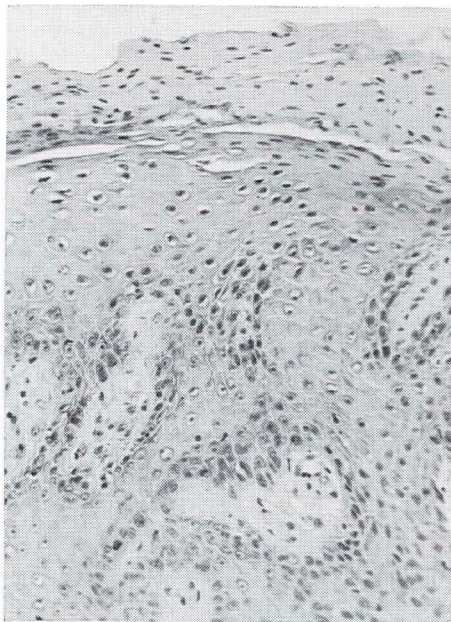


Figure 2

(Case #2) Premalignant leukoplakia. There is irregular maturation of cells with retention of nuclei in the keratin layer. Atypical cells in the basal layer are seen in the lower midportion and on the left.

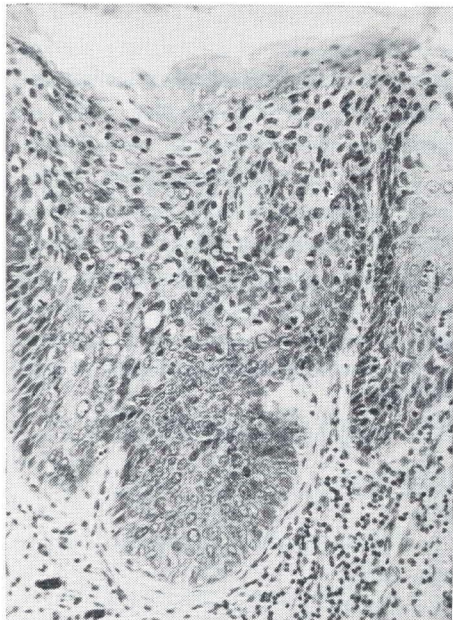


Figure 3

(Case #4) Carcinoma in situ. There is nearly complete absence of differentiation throughout the entire thickness of the epithelium.

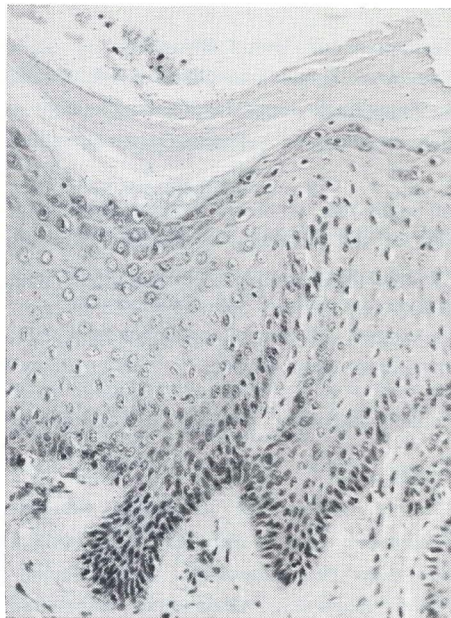


Figure 4

Epithelial hyperplasia, biopsy of vulva. Hyperkeratosis and hyperplasia of prickle cell layer are present. There is no disturbance of maturation.

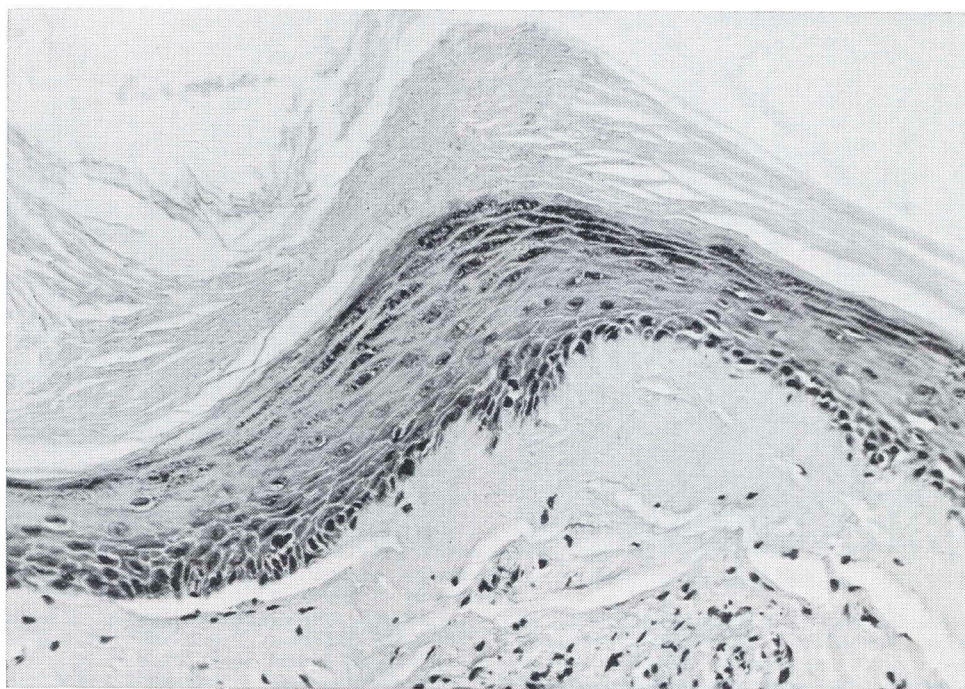


Figure 5

(Case 1.) Kraurosis. A thick keratin layer is present. Epithelial layer is atrophic and rete ridges are not evident. Subepithelial collagen is sparsely cellular and edematous.

THE LEUCOPLAKIC VULVA

PRELIMINARY CONCLUSIONS

1. During the 2 years this project has been under study 42 patients have been observed.
2. The futility of trying to segregate "white-spot" lesions of the vulva according to distinct clinical categories has been amply demonstrated.
3. Information of high practical value has come from evaluating these lesions according to impressions of pathologic cell activity.
4. The importance of procuring multiple biopsy specimens according to general field distribution of the lesion rather than upon impressions of maximum clinical activity, appears to have been well supported.
5. While the preliminary results of this project do not permit the stating of a histopathologic definition of "pre malignancy", it appears wise that a stand be taken on an arbitrary set of standards which can be subjected to the tests of time and experience.

REFERENCES

1. Parrott, M. H. and Miller, N. F.: Diseases of the vulva, *In*, Gynecology and Obstetrics, ed. by C. H. Davis and B. Carter, Hagerstown, Md., W. F. Prior Co., 1953, Vol. 2, Chap. 9.
2. Bonney, V.: The connective tissue in carcinoma and in certain inflammatory states that precede its onset, *Lancet* 1:1465, 1908.
3. Bonney, V.: Leukoplakic vulvitis and conditions liable to be confused with it, *Proc. Roy. Soc. Med.* 31:1057, 1938.
4. Berkeley, C., and Bonney, V.: Leucoplakic vulvitis and its relation to kraurosis vulvae and carcinoma vulvae, *Proc. Roy. Soc. Med.* 32:29, 1909; also *Brit. Med. J.* 2:1739, 1909.
5. Langley, I. L., Hertig, A. T. and Van Smith, G.: Relation of leucoplakic vulvitis to squamous carcinoma of the vulva, *Am. J. Obst. & Gynec.* 62:167, 1951.
6. Jeffcoate, T. N. A. and Woodcock, A. S.: Prremalignant conditions of the vulva, with particular reference to chronic epithelial dystrophies, *Brit. Med. J.* 2:127, 1961.
7. Hunt, E.: *Diseases Affecting the Vulva*, ed. 3, St. Louis, Mosby, 1948.
8. Taussig, F. J.: *Diseases of the Vulva*, New York, D. Appleton, 1923.
9. MacAfee, C. H. C.: Some aspects of vulval cancer, *J. Obst. & Gynec. Brit. Comm.* 69:177, 1962.
10. McKelvey, J. L.: Carcinoma of the vulva, *Clin. Obst. & Gynec.* 1:1101, 1958.

